



PATIENT

Saide Baig

SPECIES

Canine

BREED

Mix

SEX

Female Spayed

AGE

11.5years

WEIGHT

15.6lbs

INTERPRETED BY

Maggie Machen Lamy,
DVM, DACVIM
(Cardiology)

IMAGING PERFORMED BY

Diane McFadden

HOSPITAL NAME

Ho Ho Kus Veterinary
Hospital

REFERRING VET

Dr. Scott

INVOICE

29144

DATE

1/21/23

PRESENTING CLINICAL SIGNS

History: Recheck echo. Grade 2/6 heart murmur.

-Pertinent previous echo findings (2021 MML): Mild MR, no LA or LVE, mild TR: 2.3m/s. LA: 1.3, LV: 2.3.

ECHOCARDIOGRAM FINDINGS

2D, m-mode, color flow and doppler imaging is available. Diffuse thickening of mitral valve leaflets with no prolapse into the left atrial lumen. Trace eccentric mitral regurgitation with no left atrial dilation. Normal LV diameter with adequate myocardial function. The tricuspid valve appears mildly thickened with mild tricuspid regurgitation. Normal velocity. Normal right atrial and ventricular diameter and morphology indicating no overt evidence of pulmonary arterial hypertension. The pulmonic and aortic valves are normal in morphology and mobility. Normal pulmonic and aortic outflow velocities with laminar flow. No obvious aortic or pulmonic insufficiency. No pericardial or pleural effusion noted. No obvious cardiac masses.

CARDIAC CHART

CANINE CARDIAC PARAMETERS	MR VMAX (m/s)	TR VMAX (m/s)	LA/AO (Boon method)	LA/AO (Heart Base; Swe)	FS (%)	EF (%)	EPSS (cm)
NORMAL PARAMETER	4.5-5.5	<2.7	1.3	<1.6	28-40	40-100	<0.6
PATIENT	NM	2.6	NM	1.1	45	79	0.27
CANINE CARDIAC PARAMETERS	HR (BPM)	AV VMAX (m/s)	PV MAX (m/s)	BODY WEIGHT (kg)	LA 2D short axis Base view (cm)	LVIDd Avg; 2D and m-mode short axis (cm)	LVIDs Avg; 2D and m-mode short axis (cm)
NORMAL PARAMETER	50-100	0.7-1.7	0.7-1.6	BELOW	BELOW	BELOW	BELOW
PATIENT	92	1.1	0.8	7.1	1.5	1.8	1.0
*Normal chamber parameters expressed as a mean value (SD)							
BODY WEIGHT DEPENDENT PARAMETERS							
<i>*Note: All measurements based upon multi-modal images and methods. An average value is reported.</i>							
				3	1.27 (5.3)	2.46 (2.46)	1.36 (5.5)
				5	1.40 (4.5)	2.74 (5.2)	1.60 (4.7)
				10	1.50 (3.8)	3.27 (3.5)	2.06 (3.1)
				15	1.83 (2.0)	3.71 (2.4)	2.43 (2.1)
				20	2.02 (1.9)	4.14 (2.2)	2.80 (2.0)
				25	2.18 (2.4)	4.48 (2.9)	3.10 (2.5)
				30	2.33 (3.3)	4.83 (3.9)	3.39 (3.4)
				35	2.48 (4.3)	5.17 (5.0)	3.69 (4.5)
				40	2.62 (5.2)	5.48 (6.1)	3.96 (5.4)
				50	2.88 (7.1)	6.07 (8.3)	4.46 (7.4)

INTERPRETATION OF THE FINDINGS & FURTHER RECOMMENDATIONS

Chronic degenerative valve disease persists with trace mitral and mild tricuspid regurgitation. Compared to the prior study, findings are similar with no progression in left or right heart enlargement. No pulmonary hypertension is noted, and no additional issues are identified.

Given these findings, no cardiac medications are indicated. Assessment of progression in the future will help predict long term prognosis, which is highly variable at this stage (B1). Omega fatty acid supplementation and mild salt restriction may be of some long-term benefit. Monitor for development of a cough, labored breathing, exercise intolerance or collapse episodes.



PATIENT

Saide Baig

No cardiac contraindication for general anesthesia prior to chamber enlargement.

SPECIES

Canine

Recommend conservative monitoring with a recheck echocardiogram in 1 year, sooner if any development of clinical signs.

BREED

Mix

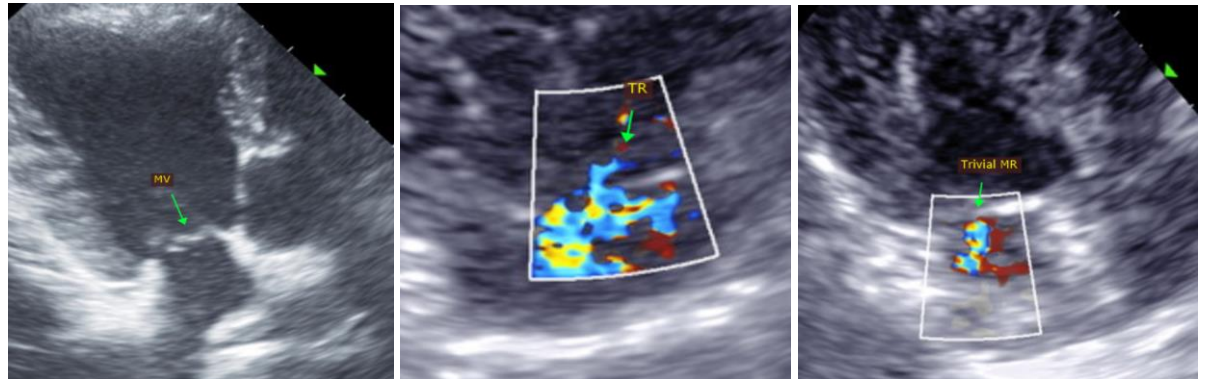
SEX

Female Spayed

AGE

11.5years

IMAGES



WEIGHT

15.6lbs

The information and recommendations provided are based on the images presented by the referring veterinarian. No evaluation can be communicated regarding pathology that was not visible in the image/video clips provided.

INTERPRETED BY

Maggie Machen Lamy,
DVM, DACVIM
(Cardiology)

Thank you for this referral. This report was generated using transcription software, and minor dictation errors may be present. If the clinical or image interpretation does not parallel your findings or if I can be of any further assistance, please contact me.

Maggie Machen Lamy, DVM
Diplomate of the American College of Veterinary Internal Medicine (Cardiology)
info@sonopath.com

IMAGING PERFORMED BY

Diane McFadden

HOSPITAL NAME

Ho Ho Kus Veterinary
Hospital

REFERRING VET

Dr. Scott

INVOICE

29144

DATE

1/21/23